



## The low intestinal and hepatic toxicity of hydrolyzed fumonisin B<sub>1</sub> correlates with its inability to alter the metabolism of sphingolipids

Bertrand Grenier<sup>a,c</sup>, Ana-Paula F.L. Bracarense<sup>b</sup>, Heidi Elisabeth Schwartz<sup>d</sup>, Catherine Trumel<sup>e</sup>, Anne-Marie Cossalter<sup>a</sup>, Gerd Schatzmayr<sup>c</sup>, Martine Kolf-Clauw<sup>a,e</sup>, Wulf-Dieter Moll<sup>c</sup>, Isabelle P. Oswald<sup>a,\*</sup>

<sup>a</sup>INRA, UMR 1331 ToxAlim, Immuno-Myco-Toxicology team, 180 chemin de Tournefeuille BP 93173, 31027 Toulouse Cedex 3, France

<sup>b</sup>Universidade Estadual de Londrina, Lab. Patologia Animal, Londrina, Brazil

<sup>c</sup>BIOMIN Research Center, Technopark 1, Tulln, Austria

<sup>d</sup>Christian Doppler Laboratory for Mycotoxin Metabolism, University of Natural Resources and Life Sciences, Vienna, Department IFA Tulln, Tulln, Austria

<sup>e</sup>Université de Toulouse, Ecole Nationale Vétérinaire, Toulouse, France

### ARTICLE INFO

#### Article history:

Received 10 January 2012

Accepted 14 February 2012

Available online 22 February 2012

#### Keywords:

Fumonisin

Hydrolyzed fumonisin

Sphingoid bases

Liver

Digestive tract

### ABSTRACT

Fumonisin is a mycotoxin frequently found as natural contaminants in maize, where they are produced by the plant pathogen *Fusarium verticillioides*. They are toxic to animals and exert their effects through mechanisms involving disruption of sphingolipid metabolism. Fumonisin B<sub>1</sub> (FB<sub>1</sub>) is the predominant fumonisin in this family. FB<sub>1</sub> is converted to its hydrolyzed analogs HFB<sub>1</sub>, by alkaline cooking (nixtamalization) or through enzymatic degradation. The toxicity of HFB<sub>1</sub> is poorly documented especially at the intestinal level. The objectives of this study were to compare the toxicity of HFB<sub>1</sub> and FB<sub>1</sub> and to assess the ability of these toxins to disrupt sphingolipids biosynthesis. HFB<sub>1</sub> was obtained by a deesterification of FB<sub>1</sub> with a carboxylesterase. Piglets, animals highly sensitive to FB<sub>1</sub>, were exposed by gavage for 2 weeks to 2.8 μmol FB<sub>1</sub> or HFB<sub>1</sub>/kg body weight/day. FB<sub>1</sub> induced hepatotoxicity as indicated by the lesion score, the level of several biochemical analytes and the expression of inflammatory cytokines. Similarly, FB<sub>1</sub> impaired the morphology of the different segments of the small intestine, reduced villi height and modified intestinal cytokine expression. By contrast, HFB<sub>1</sub> did not trigger hepatotoxicity, did not impair intestinal morphology and slightly modified the intestinal immune response. This low toxicity of HFB<sub>1</sub> correlates with a weak alteration of the sphinganine/sphingosine ratio in the liver and in the plasma. Taken together, these data demonstrate that HFB<sub>1</sub> does not cause intestinal or hepatic toxicity in the sensitive pig model and only slightly disrupts sphingolipids metabolism. This finding suggests that conversion to HFB<sub>1</sub> could be a good strategy to reduce FB<sub>1</sub> exposure.

© 2012 Elsevier Inc. All rights reserved.

### 1. Introduction

Mycotoxins are structurally low-molecular-weight metabolites produced by fungi. As secondary metabolites they are not essential to fungi growth but may contaminate animal feed and human food

at all stages of the food chain. Their worldwide occurrence is considered to be a major risk factor affecting human and animal health, and in addition leads to considerable worldwide economic losses.

Among mycotoxins, fumonisins are of major concern. These metabolites produced by *Fusarium verticillioides* and other fungi are common fungal contaminants of corn and some other grains [1]. Indeed, as much as 59% of corn and corn-based products are contaminated worldwide with variable amounts of fumonisin B<sub>1</sub> (FB<sub>1</sub>). Fumonisin B<sub>2</sub> (FB<sub>2</sub>) and B<sub>3</sub> (FB<sub>3</sub>) are simultaneously produced with FB<sub>1</sub> on grains, and the difference from FB<sub>1</sub> is related to the absence of hydroxyl group in FB<sub>2</sub> and FB<sub>3</sub> on the aminopentol backbone. However, FB<sub>1</sub> remains the most prevalent of the fumonisin subspecies, about 70–80% of the total fumonisins content [2]. Fumonisin exerts complex biological effects. The toxic effects of fumonisins range from hepatotoxicity and renal toxicity to species-specific effects such as pulmonary edema in pigs and

**Abbreviations:** AP<sub>1</sub>, aminopentol; b.w., body weight; CerS, ceramide Synthase; FB<sub>1</sub>, FB<sub>2</sub>, FB<sub>3</sub>, fumonisin B<sub>1</sub>, B<sub>2</sub>, B<sub>3</sub>; GGT, Gamma-glutamyl transferase; HE, hematoxylin-eosin; HFB<sub>1</sub>, HFB<sub>2</sub>, HFB<sub>3</sub>, hydrolyzed fumonisin B<sub>1</sub>, B<sub>2</sub>, B<sub>3</sub>; HPLC-FLD, high performance liquid chromatography with postcolumn fluorescence derivatization; IFN, interferon; IL, interleukin; IPEC-1, intestinal porcine epithelial cell line; LC-MS, liquid chromatography-mass spectrometry; MHC-II, major histocompatibility complex class II; NOAEL, no observable adverse effect level; OPA, ortho-phthalaldehyde; ppm, parts per million (or mg/kg of feed); RPL32, ribosomal protein L32; Sa, sphinganine; SEM, standard error of mean; SI, small intestine; So, sphingosine; TCA, tricarballic acids; TNF, tumor necrosis factor.

\* Corresponding author. Tel.: +33 561285480.

E-mail address: [isabelle.oswald@toulouse.inra.fr](mailto:isabelle.oswald@toulouse.inra.fr) (I.P. Oswald).

leukoencephalomalacia in horses [3,4]. In humans, exposure to fumonisins has been linked to esophageal cancer and neural tube defects [4,5]. The effect on the intestine has been less investigated but villous alterations, reduced expression of immune mediators and an increase in intestinal colonization by opportunistic pathogenic bacteria in piglets have been detected [6–8].

Fumonisin is structurally similar to sphingoid bases, and were identified as potent inhibitors of sphinganine N-acyl transferase (ceramide synthase) [9]. Toxicity and carcinogenicity of fumonisins are related to the disruption of sphingolipid metabolism that occurs as a result of inhibition of ceramide synthase [4,9].

Several strategies have been developed to reduce fumonisin exposure. The alkali treatment of FB<sub>1</sub>-contaminated maize, named nixtamalization, is widely used in Latin America, to produce tortillas [10]. This alkaline hydrolysis cleaves the tricarballic acid side chains of FB<sub>1</sub> leading to the formation of hydrolyzed fumonisin B<sub>1</sub> (HFB<sub>1</sub>). Conversion of FB<sub>1</sub> to HFB<sub>1</sub> can also be obtained by microbial degradation, through the use of fumonisin carboxylesterases, an enzyme specific of the FB<sub>1</sub> catabolism [11,12]. Carboxylesterases are ubiquitous enzymes, which can be found in tissues of all animals, and are responsible for detoxification of numerous exogenous compounds. However, so far it has not been demonstrated inside of animals a degradation of FB<sub>1</sub> through these enzymes.

Toxicity of HFB<sub>1</sub> is poorly documented. *In vitro* and *in vivo* data indicate that HFB<sub>1</sub> has a limited ability to inhibit ceramide synthase [13–15]. Hepatic and renal lesions were reported in rats fed nixtamalized material containing HFB<sub>1</sub> [16,17]. By contrast, in mice fed purified HFB<sub>1</sub>, no hepatotoxicity or pathological changes were detected [14]. Similarly, HFB<sub>1</sub> was not carcinogenic in rats [18] and did not affect fetal development through the formation of neural tube defects in either mice or rats, whether intraperitoneally or orally administered [15,19]. Thus, conflicting data exist on the toxicity of HFB<sub>1</sub>.

Pig is highly sensitive to FB<sub>1</sub> and, upon short term exposure, adverse effects are observed in this animal species at lower levels than in rodents [8,20,21]. Pig is potentially exposed to high level of FB<sub>1</sub>. In addition pig can be regarded as the most relevant animal model for extrapolating to humans, with a digestive physiology very similar to that of human [22,23].

The objectives of this study were to compare the toxicity of HFB<sub>1</sub> and FB<sub>1</sub> and to assess the ability of these toxins to disrupt sphingolipid biosynthesis using the sensitive pig model [8,21]. HFB<sub>1</sub> did not induce intestinal and hepatic toxicity at a dose level that was significantly higher than the reported NOAEL for FB<sub>1</sub> [19]. HFB<sub>1</sub> slightly disrupted sphingolipid metabolism, although much less potently than FB<sub>1</sub>. Together, the findings indicate that HFB<sub>1</sub> is less toxic than FB<sub>1</sub>, and that conversion of FB<sub>1</sub> to HFB<sub>1</sub> could be a good strategy to reduce fumonisin exposure.

## 2. Material and methods

### 2.1. Animals

Eighteen, 4-week-old weaned female piglets (Pietrain/Duroc/Large-white) were obtained locally in France. Animals were acclimatized for 1 week in the animal facility of the INRA ToxAlim Unit (Toulouse, France), prior to being used in experimental protocols. Six pigs were allocated to each treatment on the basis of body weight; control group: 10.98 ± 0.16; FB<sub>1</sub> group: 10.92 ± 0.51; HFB<sub>1</sub> group: 10.98 ± 0.46. During the 14-day experimental period, animals were given free access to water and were fed with a basal diet *ad libitum*, as previously described [21]. All animal experimentation procedures were carried out in accordance with the European Guidelines for the Care and Use of Animals for Research Purposes

(Directive 86/609/EEC). Three of the authors have an official agreement from the French Veterinary Services for animal experimentation.

### 2.2. Mycotoxins

Lyophilized culture material of *F. verticillioides*, containing 13.7 g/kg FB<sub>1</sub>, 5.2 g/kg FB<sub>2</sub>, and 1.7 g/kg FB<sub>3</sub>, was obtained from Biopure – Romer Labs Diagnostic GmbH, Tulln, Austria. Aliquots of 24.25 g culture material were resuspended in 250 mL 10 mM sodium phosphate buffer pH 7.0, homogenized with an ultraturrax, incubated at 22 °C for 30 min, and centrifuged for 10 min at 8000 rpm in a Beckman JA10 rotor. This extraction was repeated twice. The supernatants from all three extractions of all aliquots were combined, the pH was re-adjusted to 7.0, and this extract was separated into two equal halves in 5 L bottles. Fumonisin carboxylesterase FumD was prepared by fermentation of recombinant *Pichia pastoris* as previously described [11]. Lyophilized fermentation supernatant was dissolved in water at a concentration of 100 mg/mL, and 774 µL of this solution was added per liter to one of the two aliquots of extract. Both aliquots were incubated overnight at 22 °C with shaking at 60 rpm, and both were heat-inactivated by boiling in a microwave oven for one minute in aliquots of about 650 mL. A portion of the FumD solution was heat-inactivated for 40 min in a boiling water bath, and the same amount of enzyme that was used for preparation of the hydrolyzed fumonisin extract was added, in heat-inactivated form, to the intact fumonisin extract. Samples of both extracts from before, during, and after incubation were analyzed by LC–MS using a previously described method [11] to confirm that the fumonisins were hydrolyzed and intact, respectively, in the two extracts. Since more material was required, the extracts were combined with equal amounts of extracts which were prepared from the same culture material in the same way, except that water instead of 10 mM phosphate buffer was used for extraction. The final extract of intact fumonisins was analyzed by Quantas – Romer Labs Diagnostic GmbH, Tulln, Austria, using a certified LC–MS method, and found to contain 530.85 mg/L FB<sub>1</sub>, 133.30 mg/L FB<sub>2</sub>, and 35.60 mg/L FB<sub>3</sub>. Extracts were stored at –20 °C. For the no fumonisins control group, 5 mM sodium phosphate containing the same concentration of heat-inactivated FumD as the two extracts was made.

### 2.3. Experimental design and tissue/blood sampling

Animals received daily by gavage the different solutions (control, FB<sub>1</sub>, HFB<sub>1</sub>) at the concentration of 2.8 µmol FB<sub>1</sub>/kg b.w./day. At weekly time intervals, blood samples were aseptically collected from the left jugular vein. Blood was collected in tubes containing sodium heparin for biochemistry, or citrate for fibrinogen measurement (Vacutainer<sup>®</sup>, Becton-Dickinson, USA). Plasma samples were obtained after centrifugation of blood and stored at –20 °C for later analysis. Upon termination of the experiment, corresponding to 14 days of dietary exposure to treatments, immediately after electrical stunning, pigs were killed by exsanguinations, and liver and the entire gastrointestinal tract were removed. The mesentery was cut using scissors, and the small intestine (SI) was aligned on a table and measured without applying tension. The SI was divided into three parts of equal length, and 15 cm tissue segments were collected from the middle of each part (named in the present study as Proximal SI, Mid SI and Distal SI). Subsamples of the SI segments were either fixed in 10% buffered formalin (Sigma, Saint-Quentin Fallavier, France) for histopathological analysis or flash-frozen in liquid nitrogen and stored at –80 °C until RNA extraction. Liver and mesenteric nodes were similarly prepared, and for liver an additional piece of hepatic

tissue (5–15 g for each animal) was kept at  $-80^{\circ}\text{C}$  until sphingolipid analysis.

#### 2.4. Biochemistry

Plasma concentrations of albumin, total proteins, cholesterol, triglycerides, fibrinogen and activity of gamma-glutamyl transferase were determined by a Vitros 250 analyzer (Ortho Clinical Diagnostics, Issy les Moulineaux, France) at the Veterinary School of Toulouse (France).

#### 2.5. Determination of sphinganine (Sa)/sphingosine (So) ratios

Assessment of sphingolipid metabolism, by measurement of the content of sphingoid bases in plasma and liver samples, was carried out according to Yoo et al. [24] with some modifications. In short, 200  $\mu\text{L}$  aliquots of plasma samples were spiked with  $\text{C}_{17}$ -sphingosine and  $\text{C}_{20}$ -sphinganine (Avanti Polar Lipids, Alabama, USA) as internal standards, 400  $\mu\text{L}$  of chloroform (p.a., Merck, Darmstadt, Germany) and 1.3 mL of methanolic potassium hydroxide solution (0.154 M reagents from Merck) were added and samples were shaken at  $37^{\circ}\text{C}$  for 1 h. After further addition of 1.2 mL of chloroform, the chloroform phase was washed three times with alkaline water (samples vortexed and centrifuged at 2500 rpm for 5–8 min between each washing) and subsequently evaporated to dryness. The residues were derivatized using OPA reagent (final volume 300  $\mu\text{L}$ ) according to Riley et al. [25] and the resulting solutions were measured by HPLC-FLD. For analysis of liver samples, aliquots of frozen liver samples were homogenized on ice in the fourfold volume of cold phosphate buffer. Then, 100  $\mu\text{L}$  aliquots of the homogenates were diluted with 100  $\mu\text{L}$  of water and worked up and analyzed in the same way as the plasma samples.

For HPLC-FLD analysis, 25  $\mu\text{L}$  of derivatized standards or sample extracts were injected into the HPLC-system (Agilent 1100 series, Waldbronn, Germany) and separated on a C6 phenyl column (50 mm  $\times$  2 mm, 5  $\mu\text{m}$ , Phenomenex, Aschaffenburg, Germany) equipped with a pre-column of the same stationary phase at 0.5 mL/min using gradient elution. Mobile phase A and B consisted of methanol (gradient grade for LC, Merck)/water/glacial acetic acid (p.a., Merck) (A: 60:39.9:0.1, v/v/v; B: 90:9.9:0.1, v/v/v). The following gradient was used: 0 min: 0% B, 4.5 min: 84% B, 6.8 min: 90%, 9 min: 90% B, 9.5 min: 100% B, 13.9 min: 100% B, 14 min: 0% B, 16 min: 0% B. Analytes were detected fluorimetrically (excitation at 335 nm, emission at 440 nm). Concentrations of Sa and So were determined on the basis of external calibration functions and the Sa/So ratio was calculated for each animal in the biological samples.

#### 2.6. Determination of tissue lesions and villous morphometry

The tissue pieces were dehydrated through graded alcohols and embedded in paraffin wax. Sections of 3  $\mu\text{m}$  were stained with hematoxylin-eosin (HE, Sigma) for histopathological evaluation. Microscopic observations in liver and in SI were quantified as already described [21,26] with minor modifications (Table 1). A lesion score per animal was established by taking into account the importance degree of the lesion (severity factor) and its extent (intensity or observed frequency; scored from 0 to 3). Morphometry was evaluated in the different segments of intestine, by measuring the villi height randomly on thirty villi using a MOTIC Image Plus 2.0 ML<sup>®</sup> image analysis system, as already described [26]. To evaluate lesions and morphometry in these tissues, the slides were observed in a blind way by the same pathologist, and irrespective of the experimental groups.

**Table 1**

Establishment of a lesion score – endpoints used to evaluate histological lesions in liver and in the small intestine.

Tissue	Type of lesions (severity factor)	Maximal score
Liver	Disorganization of hepatic cords (1)	21
	Hepatic cell vacuolization (1)	
	Inflammatory infiltrate (1)	
	Megalocytosis (2)	
	Necrosis (2)	
Small intestine	Lymphatic vessels dilation (1)	21
	Interstitial edema (2)	
	Villi atrophy (2)	
	Villi fusion (2)	

Notes: the score for each lesion was obtained by multiplying the severity factor by the extent of the lesion. The organ score was then obtained by calculating the sum of each lesion score. Severity factor (or degree of severity), 1 = mild lesions, 2 = moderate lesions; the extent of each lesion (intensity or observed frequency) was evaluated and scored as 0 = no lesion, 1 = low extent, 2 = intermediate extent, 3 = large extent.

#### 2.7. Expression of mRNA encoding for cytokines by real-time PCR

Tissue RNA was processed in lysing matrix D tubes (MP Biomedicals, Illkirch, France) containing guanidine-thiocyanate acid phenol (Extract-All<sup>®</sup>, Eurobio, les Ulis, France) for use with the FastPrep-24 (MP Biomedicals, Illkirch, France). Concentrations, integrity and quality of RNA were determined spectrophotometrically (O.D.<sub>260</sub>) using Nanodrop ND1000 (Labtech International, Paris, France). The steps and conditions of reverse transcription and real-time PCR were performed as previously described [21,26]. The sequences of the primers used in PCR are detailed in Table 2. Primers were purchased from Invitrogen (Cergy Pontoise, France). Amplification efficiency and initial fluorescence were determined by DART-PCR method. Then, the values obtained were normalized by both house-keeping genes  $\beta 2$ -microglobulin and ribosomal protein L32 (RPL32). Finally, gene expression was expressed relative to the control group.

#### 2.8. Statistical analysis

Following the Fisher test on equality of variances, one way ANOVA using Statview software 5.0 (SAS Institute, Cary, NC, USA) was used to analyze the differences between the different treatment groups of animals at each time point. *P* values of 0.05 were considered significant.

### 3. Results

#### 3.1. Comparative effects of FB<sub>1</sub> and HFB<sub>1</sub> on the liver

Ingestion of FB<sub>1</sub> has been demonstrated to be hepatotoxic [3,4]. It was thus of interest to compare the effect of ingestion of FB<sub>1</sub> and HFB<sub>1</sub> on the liver.

##### 3.1.1. Histopathology

The lesions observed in the liver were mild to moderate for all the animals. The main lesions observed in piglets treated with FB<sub>1</sub> were a nuclear vacuolization of hepatocytes, and megalocytosis. One piglet also presented signs of necrosis. As indicated by the lesion score, animals fed FB<sub>1</sub> displayed significant liver lesions when compared to control animal ( $p < 0.001$ , Fig. 1). By contrast, the lesion score observed in animals fed HFB<sub>1</sub> was similar to the one observed in control animals, indicating that HFB<sub>1</sub> did not induce severe liver damages.

**Table 2**

Nucleotide sequences of primers for real-time PCR.

Gene	Primer concentration and sequence		Amplicon size	Genbank no.	References
RPL32	F (300 nM)	TGCTCTCAGACCCCTTGTGAAG	106	NM_001001636	[50]
	R (300 nM)	TTTCCGCCAGTTCCGCTTA			
$\beta$ 2-microglobulin	F (900 nM)	TTCTACCTTCTGGTCCACACTGA	162	NM_213978	[28]
	R (300 nM)	TCATCCAACCCAGATGCA			
IL-12p40	F (300 nM)	GGTTTCAGACCCGACGAACCTCT	112	NM_214013	[28]
	R (900 nM)	CATATGCCACAATGGGAGATG			
IL-8	F (300 nM)	GCTCTCTGTGAGGCTGCAGTTC	79	NM_213867	[21]
	R (900 nM)	AAGGTGTGGAATGCGTATTATGC			
IL-1 $\beta$	F (300 nM)	GAGCTGAAGGCTCTCCACCTC	87	NM_001005149	[28]
	R (300 nM)	ATCGCTGTCATCTCCTTGACAC			
IL-6	F (300 nM)	GGCAAAAGGGAAGAATCCAG	87	NM_214399	[21]
	R (300 nM)	CGTTCTGTGACTGCAGCTTATCC			
IFN- $\gamma$	F (300 nM)	TGGTAGCTCTGGGAAACTGAATG	79	NM_213948	[51]
	R (300 nM)	GGCTTTGCGTGGATCTG			
TNF- $\alpha$	F (300 nM)	ACTGCACTTCGAGTTATCGG	118	NM_214022	[52]
	R (300 nM)	GGCGACGGGCTTATCTGA			
IL-2	F (300 nM)	GCCATTGCTGCTGGATTAC	159	AY294018	[53]
	R (300 nM)	CCCTCCAGAGCTTTGAGTTC			
IL-10	F (300 nM)	GGCCCAAGTGAAGAGTTTCTTTC	51	NM_214041	[26]
	R (300 nM)	CAACAAGTCGCCATCTGGT			

### 3.1.2. Biochemical analytes

Next, the effect of FB<sub>1</sub> and HFB<sub>1</sub> on plasmatic biochemical analytes, as biomarkers of liver lesion and inflammation, was compared. A time related increase in albumin, total protein concentrations, cholesterol and triglycerides, fibrinogen and gamma-glutamyl transferase (GGT) were observed in animals treated with FB<sub>1</sub> for 7 and 14 days (Table 3). Conversely, ingestion of HFB<sub>1</sub> for 7 or 14 days did not induce any change in the plasmatic biochemical analytes (Table 3) when compared with the values measured for control animals.

### 3.1.3. Cytokines expression

Liver also produces cytokines, with pro- or anti-inflammatory properties. The comparative effect of the ingestion of FB<sub>1</sub> and HFB<sub>1</sub> on the expression of cytokine mRNA in the liver was analyzed and described in Table 4. In FB<sub>1</sub>-treated animals, an increased liver expression of IL-1 $\beta$  and IL-8 mRNA was observed when compared to control animals (+55% and +82% respectively). The ingestion of the toxin also significantly decreased the liver expression of IL-6, IL-10, IL-18 and IFN- $\gamma$  (–28%, –51%, –40% and –31% respectively, when compared to control).

By contrast, 14 days of exposure to HFB<sub>1</sub>, had only a minor effect on the liver expression of cytokines. Among the 6 cytokines measured, HFB<sub>1</sub> significantly modulated only the expression of IL-6 (–29% when compared to control group).

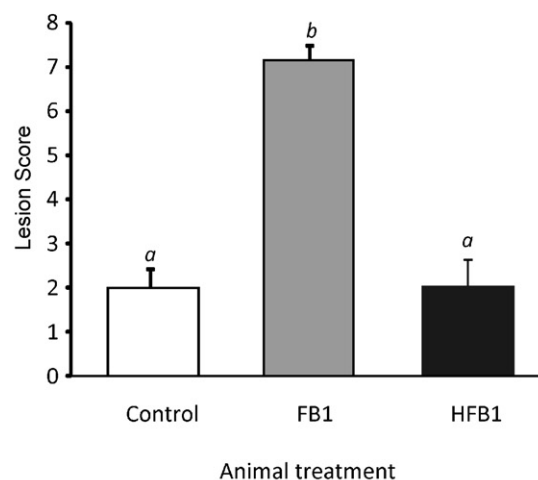
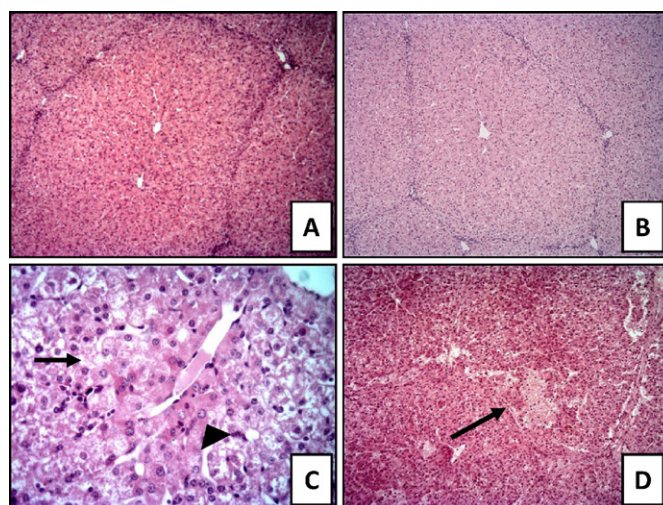
Taken together, these data indicate that ingestion of HFB<sub>1</sub> induced minimal liver toxicity as measured by the liver lesion (Fig. 1), blood biochemistry (Table 3) and liver cytokine expression (Table 4).

### 3.2. Comparative effects of FB<sub>1</sub> and HFB<sub>1</sub> on the small intestine

The digestive tract is the first compartment exposed to mycotoxins and several studies have demonstrated that the intestine is a target for FB<sub>1</sub> [27]. The effect of FB<sub>1</sub> and HFB<sub>1</sub> were compared along the small intestine (SI).

#### 3.2.1. Histopathology

As already observed in the liver, the intestinal lesions were mild to moderate. Ingestion of FB<sub>1</sub> induced lymphatic vessel dilation and interstitial edema in the proximal-SI, as well as lymphatic vessel dilation, villi atrophy and fusion, in both mid- and distal-SI.



**Fig. 1.** Effects of FB<sub>1</sub> and HFB<sub>1</sub> treatments at day 14 on the liver. Pigs were orally exposed to FB<sub>1</sub> (□), HFB<sub>1</sub> (■) or were kept as control animals (□). Liver of (A) a control pig, (B) a HFB<sub>1</sub> treated-pig and (C), (D) an FB<sub>1</sub> treated-pig. (A) and (B) normal liver architecture, HE, 10 $\times$ . (C) Hepatocyte vacuolization (arrow) and megalocytosis (arrowhead), HE, 40 $\times$ . (D) focal necrosis (arrow). HE, 10 $\times$ . Lesion scores were established after histological examination according to the severity and the extent of the lesions. Values are mean  $\pm$  SEM of 5 animals. Graphic bars without a common letter differ ( $P < 0.05$ ).



**Table 3**Effects of FB<sub>1</sub> and HFB<sub>1</sub> treatments on some biochemical values in plasma.

Biochemical parameters		Animal treatments		
		Control	FB <sub>1</sub>	HFB <sub>1</sub>
Albumin (g/L)	Day 7	26.2 ± 0.8 <sup>a</sup>	31.3 ± 0.7 <sup>b</sup>	26.1 ± 0.9 <sup>a</sup>
	Day 14	26.5 ± 1.1 <sup>a</sup>	31.6 ± 1.0 <sup>b</sup>	25.1 ± 0.7 <sup>a</sup>
Total proteins (g/L)	Day 7	49.7 ± 0.8 <sup>a</sup>	58.7 ± 1.4 <sup>b</sup>	49.9 ± 1.2 <sup>a</sup>
	Day 14	50.4 ± 0.7 <sup>a</sup>	61.4 ± 1.2 <sup>b</sup>	50.7 ± 0.6 <sup>a</sup>
Triglycerides (mmol/L)	Day 7	0.89 ± 0.12 <sup>a</sup>	1.19 ± 0.16 <sup>a</sup>	0.76 ± 0.11 <sup>a</sup>
	Day 14	0.82 ± 0.17 <sup>a</sup>	1.34 ± 0.14 <sup>b</sup>	0.82 ± 0.09 <sup>a</sup>
Cholesterol (mmol/L)	Day 7	2.70 ± 0.22 <sup>a</sup>	3.78 ± 0.21 <sup>b</sup>	2.16 ± 0.34 <sup>a</sup>
	Day 14	2.63 ± 0.26 <sup>a</sup>	4.44 ± 0.30 <sup>b</sup>	2.12 ± 0.25 <sup>a</sup>
Fibrinogen (g/L)	Day 7	2.16 ± 0.13 <sup>a</sup>	2.91 ± 0.21 <sup>b</sup>	1.89 ± 0.27 <sup>a</sup>
	Day 14	1.68 ± 0.05 <sup>a</sup>	2.96 ± 0.12 <sup>b</sup>	1.72 ± 0.05 <sup>a</sup>
GGT (U/L)	Day 7	46.0 ± 2.4 <sup>a</sup>	71.2 ± 6.2 <sup>b</sup>	53.2 ± 5.3 <sup>a,b</sup>
	Day 14	51.2 ± 1.4 <sup>a</sup>	146.2 ± 32.3 <sup>b</sup>	71.2 ± 12.8 <sup>a,b</sup>

Notes: GGT:  $\gamma$ -glutamyl transferase. Results are expressed as mean  $\pm$  SEM of five animals. Means in a row without a common letter differ ( $P < 0.05$ ).

In all sections of the small intestine, the lesion score observed in FB<sub>1</sub>-treated animals was significantly higher than the one observed in control animals ( $p < 0.05$ ,  $p < 0.001$ ,  $p < 0.05$  in proximal, mid and distal SI, respectively). Ingestion of HFB<sub>1</sub> did not elicit significant lesions in the small intestine, and the lesion scores were not statistically different from the ones observed in control animals (Fig. 2).

The morphology of the intestine was also evaluated by measuring the villi height. As reported in Table 5, FB<sub>1</sub> significantly decreased the height of villi in the small intestine (−20% and −31% mid and distal SI, respectively). By contrast, ingestion of HFB<sub>1</sub> had a moderate, non-significant effect on this parameter (Table 5).

### 3.2.2. Cytokines expression

The digestive tract is also an immune organ and the ingestion of FB<sub>1</sub> is known to modulate the intestinal expression of cytokine [6,28]. In the current study, we compared the effect of FB<sub>1</sub> and HFB<sub>1</sub> on the expression of cytokines in the different parts of the small intestine and mesenteric lymph nodes.

As shown in Fig. 3, ingestion of FB<sub>1</sub> decreased significantly the expression of mRNA encoding for IL-1 $\beta$ , IL-10, IL-2 and IFN- $\gamma$  in the proximal SI (−59%, −43%, −41%, −46%, respectively), IL-1 $\beta$ , IL-6, IL-2 and IFN- $\gamma$  in the mid SI (−38%, −33%, −38%, −46%, respectively), IL-1 $\beta$  and IL-8 in the distal SI (−56%, −42% respectively), and the levels of mRNA encoding for IL-1 $\beta$ , IL-8, IL-6, TNF- $\alpha$ , IL-2, IFN- $\gamma$  and IL-12p40 in mesenteric nodes (−51%, −59%, −14%, −27%, −24%, −29% and −45%, respectively).

Conversely, the profile of mRNA levels in the intestines from HFB<sub>1</sub>-treated animals was only slightly altered when compared to control animals. We only observed a significant alteration of IL-12p40 in the mid- and distal SI (+91% and +54%, respectively), IFN- $\gamma$  in the distal SI (+61%) as well as an alteration of TNF- $\alpha$  and IL-6 expression in the mesenteric lymph nodes (−26% and −18% respectively).

**Table 4**Effect of a 14-days exposure to FB<sub>1</sub> and HFB<sub>1</sub> on the mRNAs level of hepatic cytokines.

Cytokines	Animal treatments		
	Control	FB <sub>1</sub>	HFB <sub>1</sub>
IL-1 $\beta$	1.00 ± 0.10 <sup>a</sup>	1.55 ± 0.20 <sup>b</sup>	1.27 ± 0.21 <sup>a,b</sup>
IL-8	1.00 ± 0.09 <sup>a</sup>	1.82 ± 0.55 <sup>a</sup>	1.26 ± 0.10 <sup>a</sup>
IL-6	1.00 ± 0.08 <sup>a</sup>	0.72 ± 0.08 <sup>b</sup>	0.71 ± 0.07 <sup>b</sup>
IL-10	1.00 ± 0.15 <sup>a</sup>	0.49 ± 0.06 <sup>b</sup>	0.98 ± 0.08 <sup>a</sup>
IFN- $\gamma$	1.00 ± 0.11 <sup>a</sup>	0.69 ± 0.04 <sup>b</sup>	1.00 ± 0.25 <sup>a,b</sup>
IL-18	1.00 ± 0.01 <sup>a</sup>	0.59 ± 0.06 <sup>b</sup>	0.86 ± 0.05 <sup>a</sup>

Notes: results are expressed in arbitrary units relative to the control group. Results are mean  $\pm$  SEM of 5 animals. Means in a row without a common letter differ ( $P < 0.05$ ).

Taken together, these data indicate that when compared with ingestion of FB<sub>1</sub>, ingestion of HFB<sub>1</sub> was found to induce minimal intestinal toxicity as measured by the histopathology (Fig. 2), morphology (Table 5) and cytokine expression (Fig. 3).

### 3.3. Comparative effect of FB<sub>1</sub> and HFB<sub>1</sub> on sphingolipid metabolism

FB<sub>1</sub> disrupts sphingolipid metabolism by inhibiting ceramide synthases, leading to an increased sphinganine (Sa)/sphingosine (So) ratio in tissues and body fluids [4]. Concentrations of Sa and So were measured in plasma and liver samples from piglets belonging to the three different experimental groups and the Sa/So ratios were calculated. As expected, ingestion of FB<sub>1</sub> induced an accumulation of Sa and to a lesser extent of So both in plasma and liver of piglets. As shown in Fig. 4, the Sa/So ratios of animals treated with FB<sub>1</sub> was 8–10 fold higher in plasma and 28 fold higher in liver, when compared with control animals.

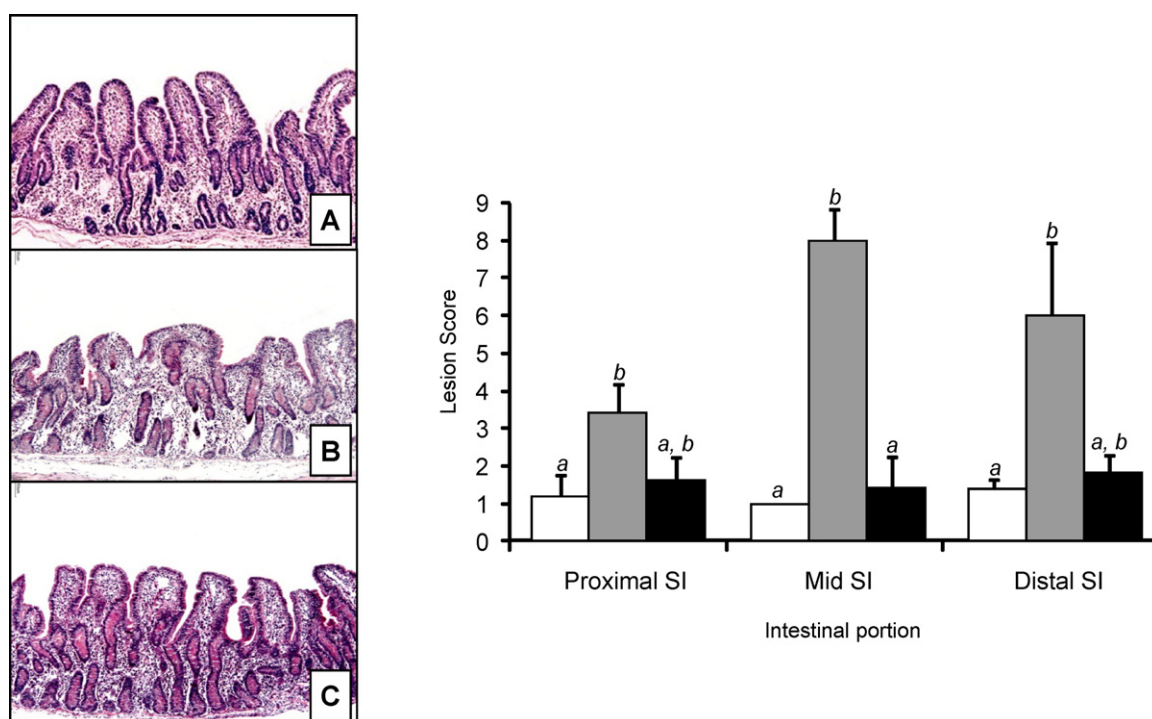
By contrast, ingestion of HFB<sub>1</sub> did not affect the sphingolipid metabolism in the plasma samples. In the liver, the Sa/So ratio was two-fold higher in animals treated with HFB<sub>1</sub> when compared with the control animals.

## 4. Discussion

The aim of the current study was to compare the *in vivo* toxicity of FB<sub>1</sub> and its fully hydrolyzed form, HFB<sub>1</sub> (also named aminopentol AP<sub>1</sub>). HFB<sub>1</sub> is produced during nixtamalization, a traditional corn treatment used in Mexico, Central America, as well as in the United States, to make masa and tortillas [10]. This alkaline hydrolysis process, using calcium hydroxide and heat, removes the tricarballic acid side chains from FB<sub>1</sub>. Processing of contaminated foods/feeds by fumonisin carboxylesterase and/or microorganisms expressing this enzyme may also lead to the formation of HFB<sub>1</sub> [11]. The data presented in this paper clearly show that hydrolysis of FB<sub>1</sub> strongly reduces its toxicity, both in the liver and the gastrointestinal tract.

In the present study, piglets were exposed to 2.8  $\mu$ mol FB<sub>1</sub> or HFB<sub>1</sub>/kg b.w./day for 14 days. This FB<sub>1</sub> concentration allowed to induce toxicity, and thus to compare at equimolar concentration the HFB<sub>1</sub> effects. Based on averaged feed consumption for pigs of this age, this dose corresponds to feed contaminated with a concentration of 37–44 mg of FB<sub>1</sub>/kg.

Over the 14 days exposure period, no effect on animal growth was observed (data not shown). This is in agreement with earlier studies where no effect on body weight gain was reported in pigs fed 47 mg FB<sub>1</sub>/kg feed [29]. Signs of hepatotoxicity were observed upon ingestion of FB<sub>1</sub>, and are in accordance with previous reports [3,4]. In the present study, biochemical markers of hepatic and



**Fig. 2.** Effects of FB<sub>1</sub> and HFB<sub>1</sub> treatments at day 14 on the small intestine (SI). Pigs were orally exposed to FB<sub>1</sub> (□), HFB<sub>1</sub> (■) or were kept as control animals (□). Mid SI of (A) control animals – continuous epithelium with normal villi, (B) FB<sub>1</sub>-treated animals – discontinuous epithelium with villi flattening and fusion, and (C) HFB<sub>1</sub>-treated animals – weak villi flattening. HE, 10×. Lesion scores were established after histological examination according to the severity and the extent of the lesions. Values are mean ± SEM of 5 animals. Graphic bars without a common letter differ ( $P < 0.05$ ).

renal lesions showed moderate increases, except GGT showing higher increase. Although this toxin is able to target different tissues or cells according to species, FB<sub>1</sub> commonly acts on the liver of both laboratory and farm animals, and affects structural integrity and functions. Microscopic changes observed in the present experiment were already described in the literature, and included a disorganization of hepatic cords, hepatocellular vacuolation, megalocytosis, apoptosis, necrosis and cell proliferation [3,4]. Similarly, biochemical changes were reported in pigs after FB<sub>1</sub> ingestion [29]. Analysis of the cytokines network upon exposure to this mycotoxin is less documented. Nevertheless, an increase of mRNA encoding for the pro-inflammatory mediators IL-1 $\beta$  and IL-8 has already been observed in the liver or the lung of treated animals [30,31]. Levels of IL-6 and IL-10, cytokines with anti-inflammatory properties [32,33], were greatly reduced in liver and could thereby confirm the inflammatory state in piglets exposed to FB<sub>1</sub> [34].

By contrast, hepatotoxicity was not observed in HFB<sub>1</sub>-treated piglets, as measured by the liver lesion, blood biochemistry and liver cytokine expression. Indeed, no microscopic lesion (megalocytosis, vacuolar degeneration) was noticed in those animals. Similarly, biochemical analytes linked with protein and lipid metabolism were not altered by the ingestion of HFB<sub>1</sub>. The

plasmatic concentrations of GGT and fibrinogen were also unaffected following HFB<sub>1</sub> exposure. These results confirm previous observations including the absence of lesions and the unmodified values of biochemical analytes in animals exposed to purified HFB<sub>1</sub> [4,15,35]. However, it should be mentioned that *in vitro*, the hydrolysis products of FB<sub>1</sub> and FB<sub>2</sub>, especially HFB<sub>2</sub> exhibited a higher cytotoxic activity on primary rat hepatocytes than their respective parent molecules [18]. In the present experiment, the liver expression of cytokines was slightly modulated in animals exposed to HFB<sub>1</sub>, but to a lesser extent than in those from that FB<sub>1</sub> group. To the best of our knowledge this is the first report on the effect of HFB<sub>1</sub> on cytokines in liver.

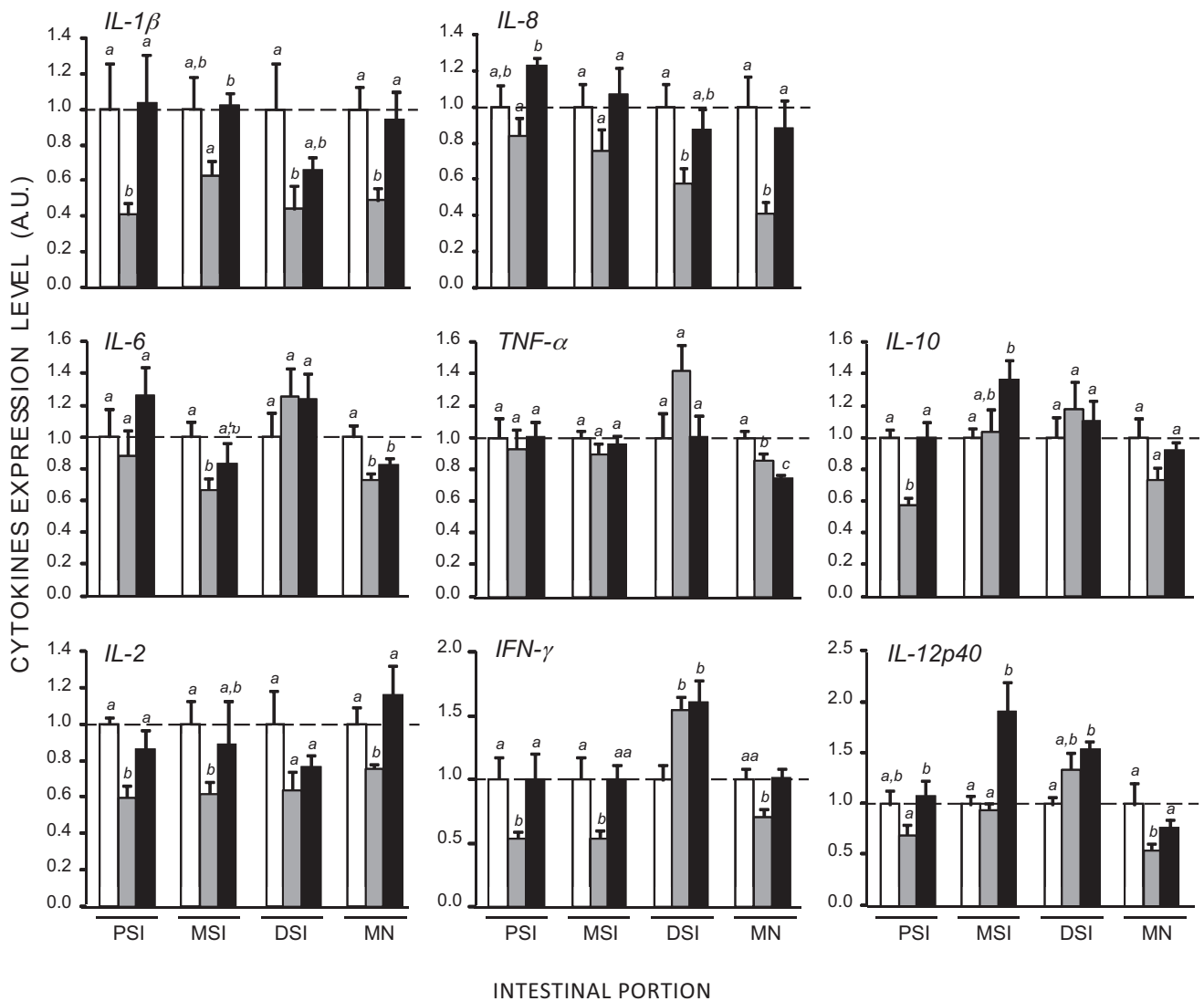
In this study, we also compared the intestinal toxicity of FB<sub>1</sub> and HFB<sub>1</sub>. The gastrointestinal tract is a primary site of mycotoxins exposure, and following ingestion of contaminated food or feed, intestinal epithelial cells could be exposed to a high concentration of toxicants, potentially affecting intestinal functions [27]. FB<sub>1</sub> was proven to affect the intestine as shown by the *in situ* inhibition of ceramide synthase [36,37]. This inhibition, could explain some adverse effects reported, such as alteration of the proliferation and the barrier function of intestinal cells [38]. In the present study, we observed that the intestine of animals exposed to this mycotoxin displayed mild to moderate tissular lesions including villi atrophy and fusion. Occurrence of these lesions was high in the intestine of animals exposed to FB<sub>1</sub>, especially in the second part of the small intestine. These findings are in agreement with the villous fusion and atrophy observed in the intestine of pigs treated with similar doses of FB<sub>1</sub> (30 ppm) [7] and in the intestine of chicks fed with 61–546 ppm FB<sub>1</sub> [39]. Effects of HFB<sub>1</sub> on the intestine are poorly documented. Most of the data concern the effect of this toxin on intestinal cell lines to assess its effect on cell viability, HFB<sub>1</sub> acylation or sphingoid bases content [35,40,41]. In the current study, we observed that ingestion of HFB<sub>1</sub> does not alter the intestinal integrity, as assessed by the villi morphometry and the lesion scores in different intestinal segments.

**Table 5**

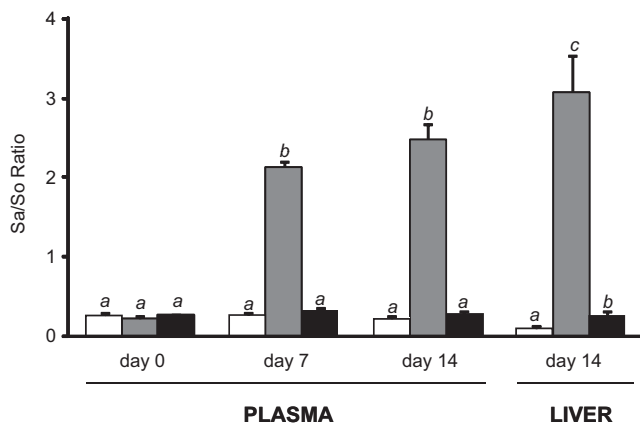
Effect of 14-days exposure to FB<sub>1</sub> and HFB<sub>1</sub> on the villi morphometry in the small intestine.

Small intestine segment	Animal treatments		
	Control	FB <sub>1</sub>	HFB <sub>1</sub>
Proximal SI	300 ± 16 <sup>a</sup>	259 ± 17 <sup>a</sup>	255 ± 19 <sup>a</sup>
Mid SI	321 ± 13 <sup>a</sup>	259 ± 21 <sup>b</sup>	297 ± 10 <sup>a,b</sup>
Distal SI	265 ± 13 <sup>a</sup>	182 ± 13 <sup>b</sup>	241 ± 7 <sup>a</sup>

Notes: results are villi height in  $\mu\text{m}$ , they are expressed as mean ± SEM for 5 animals. Means in a row without a common letter differ ( $P < 0.05$ ).



**Fig. 3.** Effects of FB<sub>1</sub> and HFB<sub>1</sub> treatments at day 14 on the mRNA levels encoding cytokines in the intestine. Pigs were orally exposed to FB<sub>1</sub> (◻), HFB<sub>1</sub> (◼) or were kept as control animals (□). Patterns of cytokine mRNA expression were assessed in the proximal, mid- and distal small intestine (PSI, MSI, DSI) as well as in the mesenteric nodes (MN). Quantification of the relative cytokine mRNA level for each sample is expressed in arbitrary units (A.U.). Values are mean  $\pm$  SEM of 5 animals. Graphic bars without a common letter differ ( $P < 0.05$ ).



**Fig. 4.** Effects of FB<sub>1</sub> and HFB<sub>1</sub> treatments on the sphinganine to sphingosine (Sa/So) ratio in plasma and liver samples. Pigs were orally exposed to FB<sub>1</sub> (◻), HFB<sub>1</sub> (◼) or were kept as control animals (□). The Sa/So ratio was determined at days 0, 7 and 14 in plasma samples, and at day 14 on liver samples. Values are mean  $\pm$  SEM of 6 animals. Graphic bars without a common letter differ ( $P < 0.05$ ).

The intestine is also an immune site where immunoregulatory mechanisms simultaneously defend against pathogens and preserve tissue homeostasis to avoid immune-mediated pathology in response to environmental challenges [42]. Few data are available with regard to the effects of FB<sub>1</sub> on the intestinal immunity, and even lesser on cytokines production. FB<sub>1</sub> decreases the expression and the synthesis of IL-8 in the porcine epithelial intestinal cell line, IPEC-1 and in the ileum of animals exposed to the toxin [6]. The FB<sub>1</sub>-induced IL-8 decrease may lead to a reduced recruitment of inflammatory cells in the intestine during infection and may participate in the observed increased susceptibility of exposed piglets to intestinal infections [8,43]. FB<sub>1</sub> exposure also leads to a reduced intestinal expression of IL-12p40, an impaired function of intestinal antigen presenting cells, with decreased upregulation of major histocompatibility complex class II molecule (MHC-II) and reduced T cell stimulatory capacity upon stimulation [28]. In the present study, a decreased expression of most of the cytokines was observed in the different part of the intestinal compartments following FB<sub>1</sub> ingestion. Indeed, an important decrease of the IL-1 $\beta$ , IL-2, IFN- $\gamma$  and to a lesser extent IL-8 mRNAs was observed in

the upper intestinal tract and in the gut-associated lymphoid tissue.

By contrast, the intestinal profile of cytokines after exposure to HFB<sub>1</sub> revealed minimal changes when compared with non-exposed animals. These changes included a slight upregulation of the expression of some cytokines in the mid and distal parts of the SI, and a slight downregulation of TNF- $\alpha$  and IL-6 mRNAs in the mesenteric nodes. In comparison to the changes induced upon FB<sub>1</sub> exposure, these HFB<sub>1</sub> effects are very weak. This suggests that animals consuming HFB<sub>1</sub> would be able to drive a correct immune response and to defend efficiently against potential invaders. To our knowledge, this is the first study investigating the effect of HFB<sub>1</sub> on the intestinal morphology and the immune response.

FB<sub>1</sub> inhibits ceramide synthase, leading to an accumulation of sphinganine and to a lesser extent of sphingosine. The Sa/So ratio is a sensitive biomarker of FB<sub>1</sub> toxicity and indicates the degree of sphingolipid metabolism disruption [9,25]. This elevation in sphinganine, a highly bioactive compound, initiates a cascade of cellular alterations that are thought to be largely responsible for the toxicity of FB<sub>1</sub>. To inhibit ceramide synthase, the aminopentol backbone of FB<sub>1</sub> competes for binding of the sphingoid base substrate, whereas the tricarballic acids (TCA) side chains interfere with binding of the fatty acid acyl-CoA [40,44]. Removal of the TCA diminishes the potency of ceramide synthase inhibition, and therefore the accumulation of sphingoid bases. In the present work, we observed that ingestion of HFB<sub>1</sub> did not block ceramide synthase, which is in line with previous reports, that the TCA moieties are required for maximal inhibition of the enzyme [13–15,18,45]. Nevertheless, it should be mentioned that HFB<sub>1</sub> is not only an inhibitor but also a substrate for acylation by ceramide synthase [35,40]. The absence of TCA allows HFB<sub>1</sub> to be acylated, and acylation was observed in the presence of palmitoyl-CoA leading to the formation of N-palmitoyl-AP<sub>1</sub>. This latter compound is highly cytotoxic for HT29 cells, and a potent inhibitor of ceramide synthase [40]. Acylation was also evaluated in rats, and while formation of N-acyl-AP<sub>1</sub> occurs and produces metabolites with fatty acids of various chain lengths, no toxicity was observed [35]. We cannot exclude that acylation occurred in our experiment, however neither increase in sphinganine concentrations nor toxicity were detected. Nonetheless, this aspect warrants further investigations, considering that there are multiple isoforms of ceramide synthase (CerS) showing different tissular expression and difference in fatty acyl-CoA selectivity. Results may also vary depending on animal species.

This paper demonstrates that ingestion of HFB<sub>1</sub> results in strongly reduced toxicity compared to ingestion of FB<sub>1</sub>. Absence of reproductive and hepatic toxicity of HFB<sub>1</sub> has already been described in rats and in mice exposed to the toxin during feeding trials or by intra-peritoneal injection [14,15,19]. The present study expands this knowledge by adding that HFB<sub>1</sub> does not induce toxic effect in the intestine (lesion, inflammatory reaction) or inflammation in the liver. Previous studies which suggested toxicity of HFB<sub>1</sub> [16,17,46] were performed with nixtamalized culture material and it has been proposed that the toxic effects were mediated by residual, partially hydrolyzed or “hidden” FB<sub>1</sub> (matrix bound forms not detected by HPLC) remaining in the nixtamalized preparations [15,35,47–49]. The HFB<sub>1</sub> used in this study was obtained by enzymatic treatment of *F. verticillioides* culture material with the fumonisin carboxylesterase FumD [11], and complete hydrolysis, i.e., absence of partially hydrolyzed fumonisins, was confirmed by LC–MS. Our results indicate that, HFB<sub>1</sub> is less toxic than FB<sub>1</sub>. Thus, enzymatic degradation of FB<sub>1</sub>, with carboxylesterase, could be a good strategy to reduce fumonisin exposure.

## Conflict of interest

None.

## Acknowledgments

B. Grenier was supported by a doctoral fellowship (CIFRE 065/2007), jointly financed by the BIOMIN Holding GmbH, ANRT (Association Nationale de la Recherche Technique) and INRA (Institut National de la Recherche Agronomique). This study was supported in part by a CAPES/COFECUB grant (no. 593/08) and a CNPq grant (no. 472048/2008-2). We would like to acknowledge the Federal Ministry of Economy, Family and Youth, and the National Foundation for Research, Technology and Development for funding the Christian Doppler Laboratory for Mycotoxin Metabolism. Furthermore, we thank the government of Lower Austria for financial support. We thank G. Jaunecker for preparing the fungal culture material, A. Frank for help with preparing the extracts, I. Schöner and A. Seeböck for assistance with the sphingolipid analyses, P. Pinton and J. Laffitte for technical assistance during the animal experiments, and C.A. Moll for help with the English.

## References

- [1] Marasas WFO. Discovery and occurrence of the fumonisins: a historical perspective. *Environ Health Perspect* 2001;109:239–43.
- [2] Binder EM, Tan LM, Chin LJ, Handl J, Ichard J. Worldwide occurrence of mycotoxins in commodities, feeds and feed ingredients. *Anim Feed Sci Technol* 2007;137:265–82.
- [3] Haschek WM, Gumprecht LA, Smith G, Tumbleson ME, Constable PD. Fumonisin toxicosis in swine: an overview of porcine pulmonary edema and current perspectives. *Environ Health Perspect* 2001;109:251–7.
- [4] Voss KA, Smith GW, Haschek WM. Fumonisin: toxicokinetics, mechanism of action and toxicity. *Anim Feed Sci Technol* 2007;137:299–325.
- [5] Gelderblom W, Marasas W. Controversies in fumonisin mycotoxicology and risk assessment. *Hum Exp Toxicol*; doi:10.1017/S0007114511004946, in press.
- [6] Bouhet S, Le dorze E, Peres S, Fairbrother JM, Oswald IP. Mycotoxin fumonisin B-1 selectively down-regulates the basal IL-8 expression in pig intestine: in vivo and in vitro studies. *Food Chem Toxicol* 2006;44:1768–73.
- [7] Piva A, Casadei G, Pagliuca G, Cabassi E, Galvano F, Solfrizzo M, et al. Activated carbon does not prevent the toxicity of culture material containing fumonisin B-1 when fed to weanling piglets. *J Anim Sci* 2005;83:1939–47.
- [8] Oswald IP, Desautels C, Laffitte J, Fournout S, Peres SY, Odin M, et al. Mycotoxin fumonisin B-1 increases intestinal colonization by pathogenic *Escherichia coli* in pigs. *Appl Environ Microbiol* 2003;69:5870–4.
- [9] Soriano JM, Gonzalez L, Catala AI. Mechanism of action of sphingolipids and their metabolites in the toxicity of fumonisin B1. *Prog Lipid Res* 2005;44:345–56.
- [10] Dombink-Kurtzman MA, Dvorak TJ, Barron ME, Rooney LW. Effect of nixtamalization (alkaline cooking) on fumonisin-contaminated corn for production of masa and tortillas. *J Agric Food Chem* 2000;48:5781–6.
- [11] Heini S, Hartinger D, Thamehl M, Vekiru E, Krska R, Schatzmayr G, et al. Degradation of fumonisin B-1 by the consecutive action of two bacterial enzymes. *J Biotechnol* 2010;145:120–9.
- [12] Hartinger D, Moll WD. Fumonisin elimination prospects for detoxification by enzymatic transformation. *World Mycotoxin J* 2011;4:271–83.
- [13] Van der Westhuizen L, Shephard GS, Snyman SD, Abel S, Swanevelder S, Gelderblom WCA. Inhibition of sphingolipid biosynthesis in rat primary hepatocyte cultures by fumonisin B-1 and other structurally related compounds. *Food Chem Toxicol* 1998;36:497–503.
- [14] Howard PC, Couch LH, Patton RE, Eppley RM, Doerge DR, Churchwell MI, et al. Comparison of the toxicity of several fumonisin derivatives in a 28-day feeding study with female B6C3F<sub>1</sub> mice. *Toxicol Appl Pharmacol* 2002;185:153–65.
- [15] Voss KA, Riley RT, Snook ME, Gelineau-Van Waes J. Reproductive and sphingolipid metabolic effects of fumonisin B-1 and its alkaline hydrolysis product in LM/Bc mice: hydrolyzed fumonisin B-1 did not cause neural tube defects. *Toxicol Sci* 2009;112:459–67.
- [16] Voss KA, Bacon CW, Meredith FI, Norred WP. Comparative subchronic toxicity studies of nixtamalized and water-extracted *Fusarium moniliforme* culture material. *Food Chem Toxicol* 1996;34:623–32.
- [17] Voss KA, Riley RT, Bacon CW, Meredith FI, Norred WP. Toxicity and sphinganine levels are correlated in rats fed fumonisin B-1 (FB<sub>1</sub>) or hydrolyzed FB<sub>1</sub>. *Environ Toxicol Pharmacol* 1998;5:101–4.
- [18] Gelderblom WCA, Cawood ME, Snyman SD, Vleggaar R, Marasas WFO. Structure-activity-relationships of fumonisins in short-term carcinogenesis and cytotoxicity assays. *Food Chem Toxicol* 1993;31:407–14.



- [19] Collins TFX, Sprando RL, Black TN, Olejnik N, Eppley RM, Shackelford ME, et al. Effects of aminopentol on in utero development in rats. *Food Chem Toxicol* 2006;44:161–9.
- [20] EFSA. Opinion of the scientific panel on contaminants in food chain on a request from the Commission related to fumonisins as undesirable substances in animal feed. *EFSA J* 2005; 235:1–32.
- [21] Grenier B, Loureiro-Bracarense AP, Lucio J, Pacheco GD, Cossalter AM, Moll WD, et al. Individual and combined effects of subclinical doses of deoxynivalenol and fumonisins in piglets. *Mol Nutr Food Res* 2011;55:761–71.
- [22] Rothkott HJ, Sowa E, Pabst R. The pig as a model of developmental immunology. *Hum Exp Toxicol* 2002;21:533–6.
- [23] Guilloteau P, Zabielski R, Hammon HM, Metges CC. Nutritional programming of gastrointestinal tract development. Is the pig a good model for man? *Nutr Res Rev* 2010;23:4–22.
- [24] Yoo HS, Norred WP, Riley RT. A rapid method for quantifying free sphingoid bases and complex sphingolipids in microgram amounts of cells following exposure to fumonisin B1. *Toxicol In Vitro* 1996;10:77–84.
- [25] Riley RT, Wang E, Merrill Jr AH. Liquid chromatographic determination of sphinganine and sphingosine: use of the free sphinganine-to-sphingosine ratio as a biomarker for consumption of fumonisins. *J AOAC Int* 1994;77: 533–40.
- [26] Bracarense APFL, Lucio J, Grenier B, Pacheco GD, Moll WD, Schatzmayr G, Oswald IP. Chronic ingestion of deoxynivalenol and fumonisin, alone or in interaction, induces morphological and immunological changes in the intestine of piglets. *Br J Nutr*; doi:10.1017/S0007114511004946, in press.
- [27] Bouhet S, Oswald IP. The intestine as a possible target for fumonisin toxicity. *Mol Nutr Food Res* 2007;51:925–31.
- [28] Devriendt B, Gallois M, Verdonck F, Wache Y, Bimczok D, Oswald IP, et al. The food contaminant fumonisin B-1 reduces the maturation of porcine CD11R1(+) intestinal antigen presenting cells and antigen-specific immune responses, leading to a prolonged intestinal ETEC infection. *Vet Res* 2009;40:40.
- [29] Harvey RB, Edrington TS, Kubena LF, Elissalde MH, Casper HH, Rottinghaus GE, et al. Effects of dietary fumonisin B-1-containing culture material, deoxynivalenol-contaminated wheat, or their combination on growing barrows. *Am J Vet Res* 1996;57:1790–4.
- [30] Bhandari N, Brown CC, Sharma RP. Fumonisin B-1-induced localized activation of cytokine network in mouse liver. *Food Chem Toxicol* 2002;40:1483–91.
- [31] Halloy DJ, Gustin PG, Bouhet S, Oswald IP. Oral exposure to culture material extract containing fumonisins predisposes swine to the development of pneumonitis caused by *Pasteurella multocida*. *Toxicology* 2005;213:34–44.
- [32] De Vries JE. Immunosuppressive and anti-inflammatory properties of interleukin 10. *Ann Med* 1995;27:537–41.
- [33] Xing Z, Gauldie J, Cox G, Baumann H, Jordana M, Lei XF, et al. IL-6 is an antiinflammatory cytokine required for controlling local or systemic acute inflammatory responses. *J Clin Invest* 1998;101:311–20.
- [34] Marin DE, Taranu I, Pascale F, Lionide A, Burlacu R, Bailly JD, et al. Sex-related differences in the immune response of weanling piglets exposed to low doses of fumonisin extract. *Br J Nutr* 2006;95:1185–92.
- [35] Seiferlein M, Humpf HU, Voss KA, Sullards MC, Allegood JC, Wang E, et al. Hydrolyzed fumonisins HFB1 and HFB2 are acylated *in vitro* and *in vivo* by ceramide synthase to form cytotoxic N-acyl-metabolites. *Mol Nutr Food Res* 2007;51:1120–30.
- [36] Enongene EN, Sharma RP, Bhandari N, Voss KA, Riley RT. Disruption of sphingolipid metabolism in small intestines, liver and kidney of mice dosed subcutaneously with fumonisin B-1. *Food Chem Toxicol* 2000;38:793–9.
- [37] Loiseau N, Debrauwer L, Sambou T, Bouhet S, Miller JD, Martin PG, et al. Fumonisin B-1 exposure and its selective effect on porcine jejunal segment: sphingolipids, glycolipids and trans-epithelial passage disturbance. *Biochem Pharmacol* 2007;74:144–52.
- [38] Bouhet S, Hourcade E, Loiseau N, Fikry A, Martinez S, Roselli M, et al. The mycotoxin fumonisin B-1 alters the proliferation and the barrier function of porcine intestinal epithelial cells. *Toxicol Sci* 2004;77:165–71.
- [39] Javed T, Bunte RM, Dombink-Kurtzman MA, Richard JL, Bennett GA, Cote LM, et al. Comparative pathologic changes in broiler chicks on feed amended with *Fusarium proliferatum* culture material or purified fumonisin B-1 and moniliformin. *Mycopathologia* 2005;159:553–64.
- [40] Humpf HU, Schmelz EM, Meredith FI, Vesper H, Vales TR, Wang E, et al. Acylation of naturally occurring and synthetic 1-deoxysphingamines by ceramide synthase – formation of N-palmitoyl-aminopentol produces a toxic metabolite of hydrolyzed fumonisin AP1, and a new category of ceramide synthase inhibitor. *J Biol Chem* 1998;273:19060–64.
- [41] Schmelz EM, Dombink-Kurtzman MA, Roberts PC, Kozutsumi Y, Kawasaki T, Merrill AH. Induction of apoptosis by fumonisin B-1 in HT29 cells is mediated by the accumulation of endogenous free sphingoid bases. *Toxicol Appl Pharmacol* 1998;148:252–60.
- [42] Ramiro-Puig E, Perez-Cano FJ, Castellote C, Franch A, Castell M. The bowel: A key component of the immune system. *Rev Esp Enferm Dig* 2008;100:29–34.
- [43] Oswald IP, Comera C. Immunotoxicity of mycotoxins. *Rev Med Vet* 1998;149: 585–90.
- [44] Desai K, Sullards MC, Allegood J, Wang E, Schmelz EM, Hartl M, et al. Fumonisin and fumonisin analogs as inhibitors of ceramide synthase and inducers of apoptosis. *Biochem Biophys Acta* 2002;1585:188–92.
- [45] Flynn TJ, Stack ME, Troy AL, Chirtel SJ. Assessment of the embryotoxic potential of the total hydrolysis product of fumonisin B-1 using cultured organogenesis-staged rat embryos. *Food Chem Toxicol* 1997;35:1135–41.
- [46] Hendrich S, Miller KA, Wilson TM, Murphy PA. Toxicity of *Fusarium proliferatum*-fermented nixtamalized corn-based diets fed to rats – effect of nutritional-status. *J Agric Food Chem* 1993;41:1649–54.
- [47] Kim EK, Scott PM, Lau BPY. Hidden fumonisin in corn flakes. *Food Addit Contam* 2003;20:161–9.
- [48] Burns TD, Snook ME, Riley RT, Voss KA. Fumonisin concentrations and in vivo toxicity of nixtamalized *Fusarium verticillioides* culture material: evidence for fumonisin–matrix interactions. *Food Chem Toxicol* 2008;46:2841–8.
- [49] Park JW, Scott PM, Lau BPY, Lewis DA. Analysis of heat-processed corn foods for fumonisins and bound fumonisins. *Food Addit Contam* 2004;21:1168–78.
- [50] Pinton P, Braicu C, Nougayrede JP, Laffitte J, Taranu I, Oswald IP. Deoxynivalenol impairs porcine intestinal barrier function and decreases the protein expression of claudin-4 through a mitogen-activated protein kinase-dependent mechanism. *J Nutr* 2010;140:1956–62.
- [51] Royae AR, Husmann RJ, Dawson HD, Calzada-Nova G, Schnitzlein WM, Zuckermann FA, et al. Deciphering the involvement of innate immune factors in the development of the host response to PRRSV vaccination. *Vet Immunol Immunopathol* 2004;102:199–216.
- [52] Meisssonier GM, Pinton P, Laffitte J, Cossalter AM, Gong YY, Wild CP, et al. Immunotoxicity of aflatoxin B1: impairment of the cell-mediated response to vaccine antigen and modulation of cytokine expression. *Toxicol Appl Pharmacol* 2008;231:142–9.
- [53] Meurens F, Berri M, Auray G, Melo S, Levast B, Virlogeux-Payant I, et al. Early immune response following *Salmonella enterica* subspecies enterica serovar typhimurium infection in porcine jejunal gut loops. *Vet Res* 2009;40:5.